


**PATIENT**

Oliver Moura

**SPECIES**

Canine

**BREED**

Lab

**SEX**

Male Neutered

**AGE**

9 years

**WEIGHT**

90.2lbs

**INTERPRETED BY**

 Maggie Machen Lamy,  
 DVM DACVIM  
 (Cardiology)

**IMAGING PERFORMED BY**

Kelly Reschny, RVT

**HOSPITAL NAME**

 Main Street Animal  
 Hospital

**REFERRING VET**

Dr. Veysey

**INVOICE**

31463

**DATE**

6/21/23

**PRESENTING CLINICAL SIGNS**

History: Presented for a progressive cough. PE: Revealed no murmur, no arrhythmia. Represented for a persistent cough and heavy breathing. CXR performed: Suspect pneumonia and possible neoplasia. RX'd Clavaseptin 500mg - 1 tab PO BID 14d and Metacam 35kg dose PO SID 14d. Presented again after a collapse episode. Increased abdominal effort was noted. RX'D Baytril 150mg - 2 tabs PO SID 5d. Current Medications Thyro-Tabs 0.5mg BID, Apoquel 16mg 1.5 tabs SID, Clavaseptin 500mg BID, Metacam SID, Baytril 150mg 2 tabs SID. -CXR report: Cardiomegaly, opacity in lungs.

**ECHOCARDIOGRAM FINDINGS**

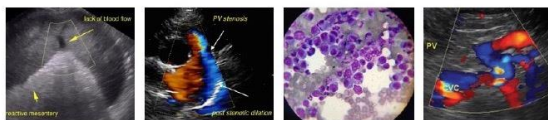
2D, m-mode, color flow and doppler imaging is available. Severe left ventricular dilation with diminished systolic function. Decreased LV wall thickness with increased sphericity. Severe left atrial enlargement. The mitral valve appears normal in form and function, with no obvious prolapse into the left atrial lumen. Moderate central mitral regurgitation secondary to annular stretch. Decreased MR velocity. Moderate tricuspid regurgitation. Moderate right atrial and ventricular dilation. TR velocity consistent with early pulmonary hypertension. The aortic valve is normal in morphology and mobility. No subvalvular ridge present; normal LVOT velocity. No aortic insufficiency. Normal pulmonic valve with trace pulmonic insufficiency seen. No pericardial or pleural effusion noted. No obvious cardiac tumors. Moderate volume ascites seen on abdominal images.

**CARDIAC CHART**

CANINE CARDIAC PARAMETERS	MR VMAX (m/s)	TR VMAX (m/s)	LA/AO (Boon method)	LA/AO (Heart Base; Swe)	FS (%)	EF (%)	EPSS (cm)
NORMAL PARAMETER	4.5-5.5	<2.7	1.3	<1.6	28-40	40-100	<0.6
PATIENT	4.2	3.0	NM	2.5	14	22	2.0
CANINE CARDIAC PARAMETERS	HR (BPM)	AV VMAX (m/s)	PV MAX (m/s)	BODY WEIGHT (kg)	LA 2D short axis Base view (cm)	LVIDd Avg; 2D and m-mode short axis (cm)	LVIDs Avg; 2D and m-mode short axis (cm)
NORMAL PARAMETER	50-100	0.7-1.7	0.7-1.6	BELOW	BELOW	BELOW	BELOW
PATIENT	NM	2.7	0.6	40.9	4.0	6.6	5.7
*Normal chamber parameters expressed as a mean value (SD)				3	1.27 (5.3)	2.46 (2.46)	1.36 (5.5)
<b>BODY WEIGHT DEPENDENT PARAMETERS</b>				5	1.40 (4.5)	2.74 (5.2)	1.60 (4.7)
*Note: All measurements based upon multi-modal images and methods. An average value is reported.				10	1.50 (3.8)	3.27 (3.5)	2.06 (3.1)
				15	1.83 (2.0)	3.71 (2.4)	2.43 (2.1)
				20	2.02 (1.9)	4.14 (2.2)	2.80 (2.0)
				25	2.18 (2.4)	4.48 (2.9)	3.10 (2.5)
				30	2.33 (3.3)	4.83 (3.9)	3.39 (3.4)
				35	2.48 (4.3)	5.17 (5.0)	3.69 (4.5)
				40	2.62 (5.2)	5.48 (6.1)	3.96 (5.4)
				50	2.88 (7.1)	6.07 (8.3)	4.46 (7.4)

**INTERPRETATION OF THE FINDINGS & FURTHER RECOMMENDATIONS**

Unfortunately, this patient has significant cardiomyopathy and systolic dysfunction. This is causing dilation and volume overload of both the left and right heart resulting in



**PATIENT**

Oliver Moura

insufficiency of the mitral and tricuspid valves. The severity of dysfunction and pump failure is severe, and the patient is at high risk for decompensating into congestive failure. Patient will always be at risk for right and/or left-sided CHF, development of arrhythmias/syncope and/or sudden death going forward. The finding of ascites likely suggests this patient is in biventricular heart failure.

**SPECIES**

Canine

**BREED**

Lab

**SEX**

Male Neutered

Systolic failure can be primary in nature (DCM) or secondary to taurine deficiency, myocarditis, hypothyroidism, tachycardia-induced cardiomyopathy, or infiltrative disease such as lymphoma. While primary disease is certainly possible, consider testing for primary causes that may be treatable. A troponin (cTnI) level can be submitted to further investigate infiltrative/inflammatory contribution (myocarditis). Additionally, a taurine level may be helpful (screen for malabsorption issue), and a thorough diet history given the recent correlation with grain free/boutique brand/exotic ingredient diets. Finally, further systemic evaluation for underlying infiltrative contribution such as neoplasia is also reasonable (abdominal ultrasound, etc.).

**AGE**

9 years

Regardless of cause, prognosis is guarded to poor at this stage in the disease process, with an average survival time of <6 months. The only treatable cause of systolic failure is diet/taurine deficiency, which is uncommon on commercially formulated dog foods. If the diet is of concern, highly recommend immediate diet change and taurine supplement regardless of blood taurine results. Please see the FDA website for more information.

**WEIGHT**

90.2lbs

Immediate institution of full cardiac supportive medications is recommended as below due to the finding of ascites, syncope and respiratory sings. Hospitalization should be considered if the patient is or becomes unstable. Additionally, abdominocentesis may be warranted for comfort. Cases of systolic failure are at high risk for malignant tachyarrhythmias (such as VT or rapid AF) and sudden death, and this should be expressed to the owner. Activity restriction is advised, and a baseline ECG recommended.

**INTERPRETED BY**

Maggie Machen Lamy,  
DVM DACVIM  
(Cardiology)

Elective anesthesia is not advised due to high risk for complications.

**IMAGING PERFORMED BY**

Kelly Reschny, RVT

Omega fatty acid supplementation and mild salt restriction may be of some long-term benefit. Monitor for development of a cough, worsening labored breathing, abdominal distention, exercise intolerance or collapse episodes in the future. Monitoring of sleeping breathing rates at home is recommended to assess response to medications and recurrence of CHF in the future.

**HOSPITAL NAME**

Main Street Animal  
Hospital

**PLAN:**

Baseline BP/ECG recommended. Consider hospitalization +/- abdominocentesis as discussed. Initiate aldosterone antagonist Spironolactone 1-2mg/kg PO q12h. Institute furosemide 1mg/kg PO q12h. Institute Pimobendan 0.3mg/kg PO q12h. Institute taurine 1000mg PO q12h. Diet history/change as discussed.

**REFERRING VET**

Dr. Veysey

**INVOICE**

31463

Monitor a renal panel and blood pressure in 1-2 weeks to ensure tolerance. If BP >130mmHg, institute ACEI 0.5mg/kg PO q12h. Consider cTnI, taurine level, AUS as discussed above.

**DATE**

6/21/23

A recheck echocardiogram is recommended in 4-6 months to screen for progression, sooner if clinical issues arise in the interim.



**PATIENT**

Oliver Moura

**SPECIES**

Canine

**BREED**

Lab

**SEX**

Male Neutered

**AGE**

9 years

**WEIGHT**

90.2lbs

**INTERPRETED BY**

Maggie Machen Lamy,  
DVM DACVIM  
(Cardiology)

**IMAGING  
PERFORMED BY**

Kelly Reschny, RVT

**HOSPITAL NAME**

Main Street Animal  
Hospital

**REFERRING VET**

Dr. Veysey

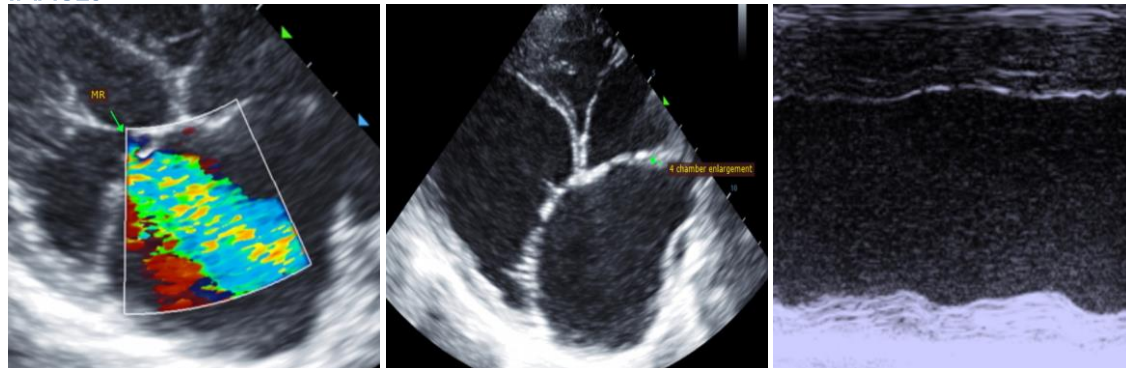
**INVOICE**

31463

**DATE**

6/21/23

**IMAGES**



The information and recommendations provided are based on the images presented by the referring veterinarian. No evaluation can be communicated regarding pathology that was not visible in the image/video clips provided.

Thank you for this referral. This report was generated using transcription software, and minor dictation errors may be present. If the clinical or image interpretation does not parallel your findings or if I can be of any further assistance, please contact me.

Maggie Machen Lamy, DVM  
Diplomate of the American College of Veterinary Internal Medicine (Cardiology)  
info@sonopath.com